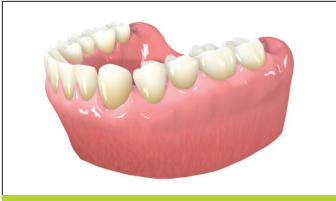
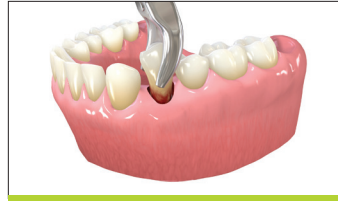
EXTRACTION SOCKET GRAFTING TECHNIQUE



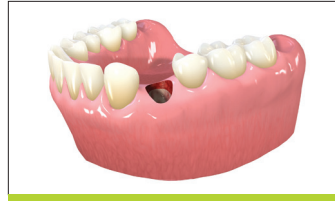Side view

1. Tooth in place, ready for extraction.



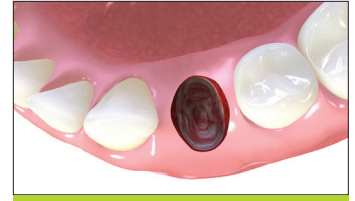Side view

2. Tooth is extracted atraumatically.

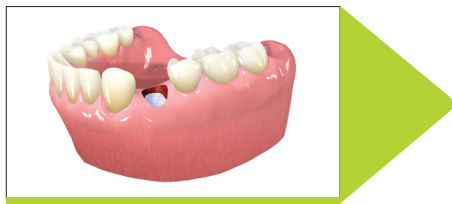

Side view

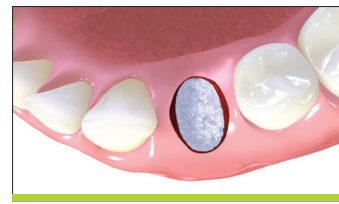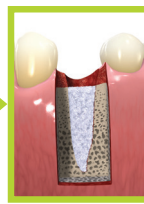
3. Extraction before grafting. All bony walls and surrounding gingiva have been preserved.



Occlusal view

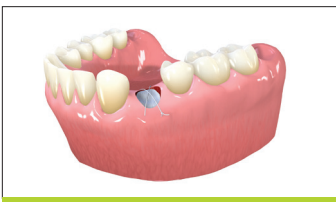

Side view

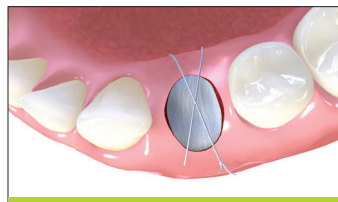


Occlusal view

4. The extraction socket has been grafted with a bone substitute material (such as Straumann® AlloGraft or Straumann® BoneCeramic®).

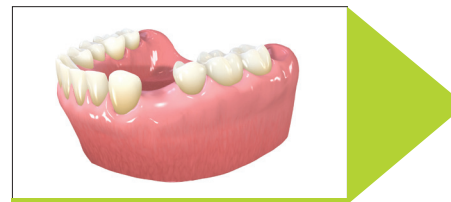

Side view

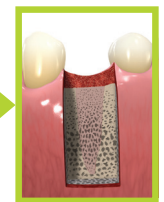


Occlusal view

5. Membrane is placed to contain the bone substitute and is secured using a cross-suture technique.



Side view



6. Healing of the soft tissue occurs over time and the socket fills in with new bone.